

Preoperative Assessment

ABFAS is looking for your preoperative clinical and radiographic assessment of the specific condition requiring/leading to the surgical procedure.



Result type: Progress Note, Podiatry
Result date: [REDACTED]
Result status: Auth (Verified)
Result title: S0377-LE
Performed by: [REDACTED]
Verified by: [REDACTED]
Encounter info: [REDACTED]
Contributor system: [REDACTED]

*** Final Report ***

DOC01455 (Verified)

CHIEF COMPLAINT/REASON FOR VISIT

Left foot fractures.

HISTORY OF PRESENT ILLNESS

[REDACTED] is a [REDACTED] who presents to my clinic today with complaints of left foot fractures. He sustained this injury on [REDACTED]. Patient notes that he was out when he stepped off a curb wrong rolling his foot. He does note that he was drinking at the time. He wore a friend's boot and crutches until he was seen on [REDACTED] where radiographs revealed displaced 3rd and 4th metatarsal fractures as well as essentially nondisplaced 2nd metatarsal fracture. He does note today that he has been ambulating on the extremity in the boot. His pain has improved to some extent.

SYSTEMS REVIEW

Denies calf pain, shortness of breath, or chest pain.

ALLERGIES

Acetaminophen and aspirin.

MEDICATIONS

Reviewed per EMR.

PAST MEDICAL/SURGICAL HISTORY

PAST MEDICAL HISTORY: Depression. Generalized anxiety. ADHD.

PAST SURGICAL HISTORY: None.

FAMILY HISTORY

Denies.

SOCIAL HISTORY

Patient is single. He does not currently use tobacco products is a former smoker, noting that he quit about 4 months ago. He consumes on an average 6 drinks per day and typically over 30 drinks per week.

PHYSICAL EXAMINATION

Printed by:
Printed on:



VITAL SIGNS:

PHYSICAL EXAMINATION

GENERAL: Patient alert, oriented, and in no apparent distress.

VASCULAR: Dorsalis pedis and posterior tibial pulses are palpable at 2/4. Capillary refill is within normal limits to all digits of the left foot. Pedal hair growth is present to the digits. No areas of necrosis noted.

DERMATOLOGIC: Skin of normal texture and turgor without signs of atrophy or open lesions. No erythema or edema noted. Toenails appear healthy without signs of discoloration or thickening.

NEUROLOGIC: Gross sensation is intact to all digits on the left foot without signs of peripheral neuropathy.

MUSCULOSKELETAL: There is edema to the left forefoot, midfoot with palpatory tenderness over the 2nd, 3rd, and 4th metatarsal midshaft fractures. There is no sign of fracture blistering or compartment syndrome. His foot compartments are soft and supple. There is no Lisfranc tenderness. Active and passive dorsiflexion and plantar flexion are intact to the level of the ankle as well as to all digits. There is no skin tenting. The skin lines are present. Remainder of forefoot, midfoot, rearfoot, and ankle is nontender to palpation. Ankle joint range of motion is smooth and largely within normal limits. Calf is soft and nontender.

DIAGNOSTICS

Three views of the left foot and ankle exhibit displaced 3rd and 4th metatarsal midshaft fractures as well as essentially nondisplaced 2nd metatarsal midshaft fracture. There is lateral translation and some degree of shortening appreciated to the 3rd and 4th metatarsal fractures. Lisfranc complex is well aligned. No other overt fractures are appreciated.

IMPRESSION/REPORT/PLAN

1. Displaced left 3rd and 4th metatarsal diaphyseal fractures.
2. Nondisplaced 2nd metatarsal diaphyseal fracture secondary to injury.

PLAN: I did review imaging and discussed findings with [REDACTED] today. At times, fractures can be treated conservatively without surgical intervention and at other times require surgical intervention. While his fractures could potentially heal in the current position, they are not in ideal alignment and are also at higher risk for delayed or nonunion, subsequent structural deformities of the foot. As a result, I would recommend surgical open reduction internal fixation of the 3rd and 4th metatarsal fractures. I discussed with them what this would entail. Patient would need to be nonweightbearing for up to 6 weeks postoperatively and with another month of protected weightbearing in a boot after that. We discussed all risks and potential complications of surgery which include but are not limited to superficial or deep infection, bone infection, nonunion, delayed union, or malunion, hardware complications, wound healing complications, temporary or permanent numbness, painful or unsightly scarring, ongoing pain despite surgical intervention, need for repeat surgical intervention, injury to adjacent structures, blood clot formation, pulmonary embolus that could be life-threatening, or complications with anesthesia that could be life-threatening. I did perform a DVT risk assessment today. Patient has no personal or familial history of thrombosis. He will be nonweightbearing postoperatively. We will have him take aspirin 81 mg 2 times a day postoperatively and perform range-of-motion exercises 5 times a day reps of 20 through all major joints. I did discuss signs and symptoms of blood clot formation or pulmonary embolus and what to do if he experiences these. We also discussed time off work. He will plan to be off work for 3 weeks at then strictly seated nonweightbearing work after that. I dispensed a short boot for him today. I also put an order for a Roll-A-Bout scooter as well. We will plan to move forward with surgical intervention on [REDACTED]. This can be performed under monitored anesthesia care in the out-patient surgical setting. Patient will obtain a preoperative history and physical prior to that time. All questions are answered per his satisfaction. Absolutely no guarantees were given or implied in regard to surgical intervention.

Op Report

Example of Op Report: Your Institution's Report May Look Different

Patient Name
Document No.
Physician
Report Type
Date of Birth

Operative Report

Account No.
Medical Record No.
Patient Location

DATE OF PROCEDURE:

SURGEON:

ASSISTANT:

PREOPERATIVE DIAGNOSES: Left foot fourth and fifth metatarsal open fracture, left foot laceration.

POSTOPERATIVE DIAGNOSES: Left foot fourth and fifth metatarsal open fracture, left foot laceration.

PROCEDURE: Open reduction and internal fixation of left fourth and fifth metatarsal repair of laceration both to the left foot.

PATHOLOGY: None.

ANESTHESIA: General.

ESTIMATED BLOOD LOSS: Less than 50 milliliters.

COMPLICATIONS: None.

INTRAOPERATIVE FINDINGS: Comminuted fracture to the left fifth metatarsal complete extraarticular displaced and a displaced fracture of the fourth metatarsal extraarticular complete as well as laceration to left foot.

INDICATIONS FOR A PROCEDURE: This is a [redacted] who was seen in the [redacted] for a left fourth and fifth metatarsal open fracture and laceration. The patient states she was trimming a tree at 1:40 this afternoon, when the patient sustained an injury to her left foot after a branch fell on her foot. The patient immediately came to the emergency room where she was found to have an open fourth and fifth metatarsal fracture. The laceration was also noted to have gross contamination from the environment. The patient was also noted to have significant bleeding at the time of the injury as well as decreased sensation to her fourth and fifth digits. The patient was taken to the OR within the 8-hour mark post-injury. The expected pre, peri and postoperative risks, benefits and potential complications were reviewed. Informed consent was signed freely and the operation took place as follows.

PROCEDURE IN DETAIL: The patient was brought to the operating room, placed in the operating table in supine position. After general endotracheal tube anesthesia, the foot was then

OPERATIVE REPORT



Example of Op Report: Your Institution's Report May Look Different

Patient Name		Account No.	
Document No.		Medical Record No.	
Physician		Patient Location	
Report Type	Operative Report		
Date of Birth			

prepped and draped using aseptic technique. Tourniquet was placed above the left calf, but was not used during the operation. Attention was then directed to the open laceration on the left foot where the laceration was then irrigated extensively and all gross contamination was removed. After irrigating with copious amounts of sterile saline, soft tissue structures were then inspected. The extensor tendons to the lesser digits of both the longus and brevis were found to be intact and of normal working condition. It was noted that 2 cutaneous nerves were found in the operation, the more medial nerve was intact; however, it was significantly injured and devoid of soft tissue coverings. There also was a lateral nerve was found in the laceration. This nerve was severed during the injury. All handling of the soft tissue was done using atraumatic technique with extensive care taken to the distal flap to preserve as much soft tissue and blood supply as possibly be obtained to the flap. Normal healthy bleeding tissue was also experienced throughout the flap. Upon inspection, the area was then again flushed with copious amounts of sterile saline. Intraoperative fluoroscopy was used to confirm fractures to both the fourth and fifth metatarsal.

Next, using 0.062-inch Kirschner wire, the wire was retrograded through the fourth metatarsal head and plantarly exiting the foot proximal to the proximal phalanx. This wire was then retrograded back through the metatarsal shaft and excellent alignment and compression was noted across the fracture site. The same procedure was then done for the fifth metatarsal, taking care to include the comminution in both distal fragments. After adequate reduction of both the fourth and fifth metatarsals using 0.0-inch Kirschner wire, the wires were then bent and cut. The area was then again flushed with copious amounts of sterile saline. At the time of the final irrigation, it was noted that 5 liters of normal saline were used in total for the irrigation. It was also noted at this time that all gross contamination was removed off from the laceration and considering the decrease infection, it also was decided to primarily close the laceration. This was achieved using combination of simple and horizontal mattress of 4-0 nylon sutures. Again, care was taken to use atraumatic technique and to preserve the distal flap as much as possible. Upon completion of the closure, the laceration was then covered with Betadine soaked moistened Owen silk, 4 x 4 gauze and Kerlix. It was noted at this time that the digits were pink and warm to the touch and the laceration margins were viable. Next, a well-padded posterior splint was then applied to the left lower extremity. The patient tolerated the procedure well without complications, was extubated successfully and left the operating room with vital signs stable and vascular status intact to the operative foot. The patient will be admitted for continued IV antibiotic, pain control and will be seen tomorrow morning during rounds.

Dictated by:

OPERATIVE REPORT

Progress Notes

Progress Note, Podiatry
* Final Report *



Example of Post-op Documentation: Your Institution's Report May Look Different

Result type: Progress Note, Podiatry
Result date: [Redacted]
Result status: Auth (Verified)
Result title: S0377-LE
Performed by: [Redacted]
Verified by: [Redacted]
Encounter info: [Redacted]
Contributor system: [Redacted]

*** Final Report ***

DOC01455 (Verified)

[Redacted] is here today for followup of open reduction internal fixation of left 3rd and 4th metatarsal fractures. Second metatarsal fracture was treated nonoperatively. He notes that his pain is well controlled at this point. He denies any falls or other issues. I had recommended a Roll-A-Bout, but he has refused this and is using crutches. He denies any other issues.

SYSTEMS REVIEW

Denies nausea, vomiting, fever, chills, calf pain, shortness of breath, or chest pain.

PHYSICAL EXAMINATION

The incision site to the left forefoot is well coated and nearly healed at this point. Sutures are intact. There is no sign of peri-incisional erythema, fluctuance, crepitus, hematoma or dehiscence. There is no peri-incisional paresthesias nor dysesthesias. Calf is soft and nontender. The 2nd, 3rd and 4th metatarsal fractures are clinically stable.

DIAGNOSTICS

Three views of the left foot exhibit no change in position as compared to previously. There is a reasonable reduction of the 3rd metatarsal fracture and anatomical alignment of the 4th metatarsal fracture. The 2nd remains nondisplaced. No hardware complications.

IMPRESSION/REPORT/PLAN

One week status post left 3rd and 4th metatarsal fracture open reduction internal fixation, 2nd metatarsal fracture treated conservatively.

PLAN: [Redacted] is progressing as anticipated at this point. I discussed with him the importance of staying strictly nonweightbearing on this extremity due to the comminuted nature of these fractures. If weightbearing earlier than instructed, this places him at much higher risk for complications, including nonunion hardware issues and need for repeat surgery. I do have some concerns that he will ambulate sooner than he is supposed to. He is to complete 6 weeks of nonweightbearing. I also strongly encouraged that he obtain a Roll-A-Bout scooter, but he is not interested in that at this time. He will continue to use the crutches. I will plan to see him back in 1 week for anticipated suture removal. He will contact me sooner with any acute issues. All questions answered.

Printed by: [Redacted]
Printed on: [Redacted]

Progress Note, Podiatry
* Final Report *



Example of Post-op Documentation: Your Institution's Report May Look Different

Result type: Progress Note, Podiatry
Result date: [Redacted]
Result status: Auth (Verified)
Result title: S0377-LE
Performed by: [Redacted]
Verified by: [Redacted]
Encounter info: [Redacted]
Contributor system: [Redacted]

*** Final Report ***

DOC01455 (Verified)

[Redacted] is here today for followup of left 3rd and 4th metatarsal fracture open reduction internal fixation. He is currently 2 weeks out from surgery and is doing well. He denies putting weight on the foot for the most part. He has not had any falls or other issues. He never did pick up the Roll-A-Bout and has just been using crutches. He denies any constitutional symptoms.

SYSTEMS REVIEW

Denies nausea, vomiting, fever, chills, calf pain, shortness of breath, or chest pain.

PHYSICAL EXAMINATION

The incision site to the left dorsal forefoot is well coated and healed today. Sutures were removed uneventfully. There is no peri-incisional erythema, fluctuance, crepitus, or signs of dehiscence. The 3rd and 4th metatarsal fractures are noted to be clinically stable as is the 2nd metatarsal fracture. The metatarsal parabola appears well aligned. Mild edema consistent with typical postoperative course.

IMPRESSION/REPORT/PLAN

Two-and-half weeks' status post left 3rd and 4th metatarsal fracture open reduction internal fixation, 2nd metatarsal fracture treated conservatively.

PLAN: I discussed findings with [Redacted]. He is progressing as anticipated at this point. Sutures were removed uneventfully. He is to remain nonweightbearing. We discussed deep vein thrombosis prophylaxis measures and what to do if he experiences these symptoms. I also did encourage him to obtain a Roll-A-Bout to make nonweightbearing more feasible longer-term for him. He is hesitant about this, but I did once again put an order in case he would like to pick this up. He does feel as though he is ready to return back to work in a nonweightbearing fashion as he does note that they have seated nonweightbearing work for him to do. Thus, I did write a note indicating that he could return to work on 09/26/2016 in a strictly nonweightbearing fashion with seated-work only.

I will plan to see patient back in 1 month with repeat radiographs or they will contact me sooner with any acute issues. All questions are answered. Radiographs can be weightbearing at the next appointment.

Printed by:
Printed on:



Progress Note, Podiatry
* Final Report *



Example of Post-op Documentation: Your Institution's Report May Look Different

Result type: Progress Note, Podiatry
Result date: [Redacted]
Result status: Auth (Verified)
Result title: S0377-LE
Performed by: [Redacted]
Verified by: [Redacted]
Encounter info: [Redacted]
Contributor system: [Redacted]

*** Final Report ***

DOC01455 (Verified)

HISTORY OF PRESENT ILLNESS

[Redacted] is here today for followup of his left thumb 3rd and 4th metatarsal fracture open reduction internal fixation as well as a 2nd metatarsal fracture treated conservatively. He does note that he has been doing well. While he can have some sensations of tightness in his foot, he denies any pain at this time. He did inadvertently stepped down hard on the foot one time, otherwise denies any falls and notes that he has been compliant with nonweightbearing with a Roll-A-Bout. Denies any new issues.

SYSTEMS REVIEW

Complete 10-point review of systems was reviewed and is negative other than that discussed in HPI. Denies calf pain, shortness of breath, or chest pain.

PHYSICAL EXAMINATION

The incision site to the left foot is well coapted and healed today. There is a small superficial eschar that was left intact with no signs of underlying wound, drainage, fluctuance, crepitus or erythema. There is appreciable palpatory tenderness over the 3rd or 4th metatarsal fracture sites, which are noted to be clinically stable. The 2nd metatarsal fracture does exhibit some mild palpatory tenderness, but was also noted to be clinically stable. The metatarsal parabola distally appears to be in satisfactory alignment. No digital deformity. Mild edema is consistent with typical postoperative course. Calf is soft and nontender.

DIAGNOSTICS

Radiographs three views of the left foot exhibit progressive interval healing at the 2nd through 4th metatarsal fracture sites. On the oblique view there is clear callus formation occurring at the 3rd metatarsal fracture site. No hardware complications or change in position as compared to previously.

IMPRESSION/REPORT/PLAN

Six weeks status post left 3rd and 4th metatarsal fracture open reduction internal fixation, 2nd metatarsal fracture treated conservatively.

PLAN: I discussed findings with [Redacted] and we did review his imaging. At this time, I would like to have him minimally touchdown weightbearing with crutches only for short distances. Otherwise, he will continue to stay off of the foot. In a few weeks he can begin to do some light protected weightbearing for short distances in the boot if it is pain-free for him to do so. Reinforced icing and elevation. He should certainly not be doing any ambulation out of the boot or he has been

Printed by:
Printed on:



Progress Note, Podiatry

* Final Report *

Example of Post-op Documentation: Your Institution's Report May Look Different

aggressive or longer distance activity in the boot. I did provide him with a note today indicating that he can continue with seated work for the next month where he is unable to accommodate, so he has been off work. All questions are answered per his satisfaction. I will plan to see him back in 1 month with repeat radiographs or he will contact me sooner with any acute issues.

Signature Line

Completed Action List:

Printed by:
Printed on:

Page 2 of 2
(End of Report)

Progress Note, Podiatry

* Final Report *

Example of Post-op Documentation: Your Institution's Report May Look Different

Result type: Progress Note, Podiatry

Result date:

Result status:

Auth (Verified)

Result title:

S0377-J.F.

Performed by:

Verified by:

Encounter info:

Contributor system:

* Final Report *

DOC01455 (Verified)

is here today for followup of left 3rd and 4th metatarsal fracture open reduction and internal fixation. He is currently about 10 weeks out from surgery. He has been back to work for a few weeks essentially doing largely seated work with some ambulation for very short distances in the boot. This has been going well for him. He denies tobacco use but does relate daily cannabis use. He does have some tenderness over the area that he points to as the 2nd metatarsal but no tenderness over the surgical site.

SYSTEMS REVIEW

Denies calf pain, shortness of breath or chest pain.

PHYSICAL EXAMINATION

The incision site to the left foot is well coated and healed today with appropriate postsurgical scarring. There are no signs of dehiscence or drainage. I am unable to elicit any palpatory tenderness over the 3rd or 4th metatarsal fractures nor other corresponding metatarsal heads, and these areas are noted to be clinically stable. There is some degree of low-grade tenderness over the midshaft of the 2nd metatarsal corresponding with the fracture site. This is also noted to be clinically stable. There is some mild tenderness sub 2nd metatarsophalangeal joint, low-grade edema consistent with typical postoperative course at this stage and continues to improve. No erythema. No peri-incisional paresthesias nor dysesthesias. Calf is soft and nontender.

DIAGNOSTICS

Three views the left foot exhibit further interval healing to the left 2nd, 3rd and 4th metatarsal fractures with interval callus formation and further obscuring to the fracture lines. There has been no interval hardware loosening or complication. There remains some mild angular deformity to the distal fragment of the 3rd metatarsal that is unchanged in alignment as compared to previously.

IMPRESSION/REPORT/PLAN

Ten weeks status post left 3rd and 4th metatarsal fracture open reduction and internal fixation, 2nd metatarsal fracture treated conservatively.

PLAN: I discussed imaging and findings with today. He does continue to progress forward. We discussed cannabis smoking cessation. For the time being, patient is to remain in boot. He is weightbearing in the boot. We will continue with current restrictions at work consisting of mainly seated work with ambulation for short distances, no heavy lifting above 15 pounds. These restrictions have been going well for him. He is to continue to avoid any excessive or

Printed by:

Printed on:

Page 1 of 2
(Continued)

Progress Note, Podiatry
* Final Report *



Example of Post-op Documentation: Your Institution's Report May Look Different

exacerbating activities with this extremity. I will plan to see him back in 1 month with repeat radiographs or he will contact me sooner with any acute issues. All questions are answered.



Signature Line
Electronically Signed By:



Completed Action List:



Printed by: |
Printed on:



Progress Note, Podiatry

* Final Report *

Example of Post-op Documentation: Your Institution's Report May Look Different

Result type: Progress Note, Podiatry

Result date:

Result status:

Auth (Verified)

Result title:

S0377 LE

Performed by:

Verified by:

Encounter info:

Contributor system:

* Final Report *

DOC01455 (Verified)

CHIEF COMPLAINT/REASON FOR VISIT

is here today for followup of left 3rd and 4th metatarsal fracture open reduction internal fixation. He is currently nearly 4 months out from surgery. He does continue to ambulate in the boot and has been doing largely seated work. This has been going well for him. He has tried to get out of the boot and walk barefoot a little bit to "test the foot" as he describes it. He denies any pain in the foot at this time when ambulatory in the boot.

SYSTEMS REVIEW

Denies calf pain, shortness of breath, or chest pain.

PHYSICAL EXAMINATION

The incision site to the left foot is well coapted and healed today with appropriate postsurgical scarring and no peri-incisional paresthesias nor dysesthesias. There is some mild persistent palpatory tenderness over the 2nd metatarsal fracture site as well as the right 3rd and 4th metatarsal heads and to a lesser extent over the 3rd and 4th metatarsal fracture sites. Overall this is improved as compared to previously. Very mild edema consistent with typical postoperative course at this stage. No palpably prominent hardware. Calf is soft and nontender.

DIAGNOSTICS

Three views of left foot exhibit interval healing to the 2nd and 4th metatarsal fracture sites. There also does appear to be some degree of increased callus formation to the 3rd metatarsal fracture site more medially, although there is persistent fracture line appreciated. No acute loosening of hardware or interval hardware complications.

IMPRESSION/REPORT/PLAN

Four months status post left 3rd and 4th metatarsal fracture open reduction internal fixation, 2nd metatarsal fracture treated conservatively.

PLAN: I discussed findings with today. We did review his imaging. He does continue to show signs of healing. The 3rd metatarsal fracture site is relatively slow to heal but does continue to progress forward. We will plan to keep him in the boot at this time and not change his work restrictions. I will plan to see him back in 1 month with repeat radiographs weightbearing of the foot. He is to abstain from any weightbearing out of the boot at this point.

Printed by:

Printed on:

Page 1 of 2
(Continued)

Progress Note, Podiatry

* Final Report *

Example of Post-op Documentation: Your Institution's Report May Look Different

Result type: Progress Note, Podiatry

Result date:

Result status:

Auth (Verified)

Result title:

S0377-LE

Performed by:

Verified by:

Encounter info:

Contributor system:

* Final Report *

DOC01455 (Verified)

is here today for followup of left 3rd and 4th metatarsal fracture open reduction internal fixation and 2nd metatarsal fracture treated conservatively. He is nearly 5 months out from surgery. He does continue to wear the boot and is doing mainly seated sedentary work at his job. He does relate "pushing the envelop" and doing more activity up on the foot than has been instructed. He denies any tobacco use or new issues. He experiences no pain in the boot whatsoever.

SYSTEMS REVIEW

Denies calf pain, shortness of breath or chest pain.

PHYSICAL EXAMINATION

The incision site to the dorsal left forefoot is well healed today with appropriate postsurgical scaring and no peri-incisional paresthesias nor dysesthesias. There is no palpably prominent hardware. There is some mild palpatory tenderness over the midshaft of the 2nd metatarsal extending into the second metatarsal, neck region. Otherwise, I am unable to elicit any palpatory tenderness whatsoever to the forefoot or midfoot today. In particular, there is absolutely no palpatory tenderness over the 3rd or 4th metatarsal fracture sites, which are both noted to be clinically stable. The metatarsal distally appears to be clinically well aligned. There is no metatarsal head or interspace pain. Digits are noted to be in satisfactory rectus alignment. Continue to decrease edema as compared to previously. Calf is soft and nontender.

DIAGNOSTICS

Radiographs: Three views of the left foot exhibit near complete healing to the 2nd metatarsal and 4th metatarsal midshaft fractures as any discrete obvious linear lucency is not well visualized at this point. This is consistent with near complete fracture healing. The 3rd metatarsal comminuted midshaft fracture remains readily visualized today with no overt interval callus formation as compared to previous radiographs on . There is no sign of hardware failure or obvious loosening of hardware as compared to previous radiographs.

IMPRESSION/REPORT/PLAN

1. Five months status post left 3rd and 4th metatarsal fracture open reduction and internal fixation, 2nd metatarsal fracture treated conservatively.
2. Delayed healing, left 3rd metatarsal midshaft fracture.

Printed by:

Printed on:

PLAN: I discussed findings with [REDACTED] today. It is important he not push his activity level as he describes he has done, as this can place him at higher risk of hardware failure and need for revisional surgery. While the 2nd and 4th metatarsal fractures continue to consolidate in and appear to be essentially nearly healed at this point, there have not been obvious signs of callus formation or further healing to the 3rd metatarsal fracture site over the last month. We discussed treatment options. I would recommend that he remain in the short boot or postop shoe at this point. I did not want him ambulating out of it at this point. He would actually prefer the boot as opposed to the postop shoe at this point and will continue with boot. We also discussed that in the setting of delayed healing, we can consider an external bone stimulator to help facilitate the bone healing process. I would not anticipate a bone stimulator to be covered by insurance at this point, which would require an out-of-pocket cost for the patient if we were to pursue that at this time. Patient is not interested in that at this time. We will continue with work restrictions to consist of protected weightbearing in the open-toed boot with no lifting greater than 20 pounds. No pushing or pulling maneuvers. Patient is instructed to inform my clinic if he is struggling with work duties or having any issues with these restrictions. Once again, he is to abstain from any weightbearing out of boot at this point or any aggressive or exacerbating activities even in the boot, both of which could place him at higher risk of hardware failure, ongoing delayed union or nonunion which could require revisional surgery. If we fail to continue to see progression of healing at the 3rd metatarsal fracture site, we will consider external bone stimulator options once this has the potential to be covered from an insurance standpoint. We discussed other potential barriers to bone healing. I discussed taking a vitamin D3 supplement on a daily basis. We could also further evaluate with vitamin D lab work today but patient would like to wait on that. Patient will contact me with any issues prior to being seen back in 1 month with repeat weightbearing radiographs of the left foot at that time.

Signature Line

Completed Action List:

Progress Note, Podiatry

* Final Report *

Example of Post-op Documentation: Your Institution's Report May Look Different

Result type: Progress Note, Podiatry

Result date:

Result status:

Auth (Verified)

Result title:

S0377-LE

Performed by:

Verified by:

Encounter info:

Contributor system:

*** Final Report ***

DOC01455 (Verified)

is here today for followup of a left 3rd and 4th metatarsal fracture open reduction, internal fixation and 2nd metatarsal fracture treated conservatively. He is currently 6 months out from surgery. He does continue with postop shoe immobilization and has been tolerating this well. He denies any overt pain to the foot at this point. He continues to wear the boot while at work and has been tolerating this well. He denies tobacco use. No new concerns or issues from the patient's standpoint at this point.

SYSTEMS REVIEW

Denies calf pain, shortness of breath, or chest pain.

PHYSICAL EXAMINATION

The incision site to the dorsal left foot is well coated and healed today with appropriate postsurgical scarring. There are no appreciable peri-incisional paresthesias nor dysesthesias. There is no appreciable palpatory tenderness over the 3rd and 4th metatarsal fracture sites which are noted to be clinically stable. There is no palpably prominent hardware appreciated. There is some mild palpatory tenderness over the midshaft of the 2nd metatarsal. There is also some mild tenderness sub 2nd and 3rd metatarsophalangeal joints although, I do not appreciate palpable deformity at the level of the metatarsophalangeal joints. No intermetatarsal space tenderness appreciated. Very low-grade edema that is near to baseline at this point. The digits are in satisfactory alignment. The calf is soft and nontender.

DIAGNOSTICS

RADIOGRAPHS: Three views of the left foot exhibit no overt sign of obvious linear lucency to the 2nd or 4th metatarsal fracture sites, consistent with healed fractures at this point. There is some callus formation at the 3rd metatarsal midshaft fracture site with no signs of interval hardware loosening or failure as compared to previous radiographs. There may be some increased callous formation as compared to previous radiographs on the oblique view although variation in angulation of radiograph as compared to previous oblique view could account for this difference. Complete osseous union across the third metatarsal fracture site has not yet been achieved, consistent with delayed healing.

IMPRESSION/REPORT/PLAN

1. Six months, status post left 3rd and 4th metatarsal fracture open reduction and internal fixation, 2nd metatarsal fracture treated conservatively.
2. Delayed healing, left 3rd metatarsal midshaft fracture.

Printed by:

Printed on:



Example of Post-op Documentation: Your Institution's Report May Look Different

PLAN: I discussed findings with [REDACTED] today. There is delayed healing of the 3rd metatarsal fracture although, this area is not really clinically tender for the patient. The hardware is noted to be clinically intact, and the fracture site is noted to be clinically stable. I discussed with [REDACTED] that at times we can consider further imaging such as a CT to evaluate extent of healing, but he would like to wait on that at this time. At this point, as there has been some progression of third metatarsal fracture healing over the last three months, I would not anticipate an external bone stimulator to be covered by insurance. We discussed out-of-pocket costs that can be associated with an external bone stimulator if not covered by insurance, and the patient does not wish to pursue that at this time, although there is potential this could be necessary at some point in the future. We did discuss working restrictions which have been going well for the patient. We will plan for work restrictions to consist of lifting no more than 25 pounds at work with no heavy pushing or pulling maneuvers. Work note was provided indicating these restrictions. He will continue with the postoperative shoe. He will continue to monitor his progress and contact us if he is struggling with his work restrictions. We also discussed continuing to take a vitamin D3 supplement on a daily basis. We will continue to closely follow this. I would like to see the patient back in 1 month with repeat weightbearing radiographs prior, or he will contact us sooner with any acute issues. All questions were answered per his satisfaction.



Signature Line



Completed Action List:



Appointment History - Select Patient:

Visit	Appt Date	Appt Time	Column	Status/ Action	User	Reason/ Appt Type	Change Date	Change Time
+	09/18/2018	11:00 AM		MOVED		SX/PO	09/11/2018	11:46 AM
+	09/11/2018	11:15 AM		COMPLETE		SX/PO	09/11/2018	11:45 AM
+	09/06/2018	09:30 AM		CANCELLED		PT IN HOSPITAL	09/06/2018	08:19 AM
	09/03/2018	09:00 AM		MADE		SURGERY	09/03/2018	04:24 PM
	09/02/2018	08:00 AM		MADE		HOSPITAL CONSULT	09/03/2018	04:22 PM
	09/01/2018	08:00 AM		MADE		HOSPITAL CONSULT	09/03/2018	04:21 PM
+	08/08/2018	04:30 PM		NOSHOW		NO SHOW	08/08/2018	05:29 PM
+	08/01/2018	01:45 PM		COMPLETE		FU	08/01/2018	03:10 PM
+	07/27/2018	04:30 PM		COMPLETE		FU	07/27/2018	05:18 PM
	06/29/2018	11:45 AM		MADE		FU	06/22/2018	11:09 AM
	06/25/2018	12:00 PM		MADE		HOSPITAL CONSULT	06/25/2018	08:19 AM
+	06/22/2018	10:15 AM		COMPLETE		FU	06/22/2018	11:09 AM
	06/18/2018	08:30 AM		MADE		HOSPITAL CONSULT	06/19/2018	08:16 AM
	06/17/2018	08:00 AM		MADE		HOSPITAL CONSULT	06/17/2018	07:49 PM
	06/16/2018	08:00 AM		MADE		HOSPITAL CONSULT	06/17/2018	07:48 PM
	06/15/2018	04:15 PM		MADE		HOSPITAL CONSULT	06/17/2018	07:46 PM
+	06/15/2018	10:45 AM		CANCELLED		GOING INTO HOSPITAL	06/15/2018	08:17 AM
+	06/08/2018	11:00 AM		COMPLETE		FU	06/08/2018	12:21 PM
	05/30/2018	07:45 AM		MADE		HOSPITAL CONSULT	05/29/2018	02:02 PM
	05/29/2018	07:15 AM		MADE		HOSPITAL CONSULT	05/29/2018	01:57 PM
	05/28/2018	07:00 AM		MADE		HOSPITAL CONSULT	05/29/2018	01:55 PM
	05/27/2018	08:00 AM		MADE		HOSPITAL CONSULT	05/29/2018	01:54 PM
	05/26/2018	08:00 AM		MADE		HOSPITAL CONSULT	05/29/2018	10:04 AM
+	05/10/2018	10:15 AM		NOSHOW		DR RESCHEDULE	05/10/2018	05:17 PM
	04/26/2018	10:30 AM		MADE		FU	05/21/2018	02:29 PM

Audit Log Appt Scheduler Moves: 3 Cancels: 2 No Shows: 2

Consultations

Labs

Example of Labs: Your Institution's Report May Look Different

Flowsheet Print Request

Patient: [REDACTED]

Printed by: [REDACTED]

MRN: [REDACTED]

Date Range: [REDACTED]

Event Date	Event	Result	Ref. Range	Status
[REDACTED]	Hgb	15.6 g/dL	(13.5 - 17.5)	
	Hct	45.2 %	(38.8 - 50.0)	
	WBC	7.3 x10(9)/L	(3.5 - 10.5)	
	RBC	4.96 x10(12)/L	(4.32 - 5.72)	
	MCV	91.1 fL	(81.2 - 95.1)	
	RDW	13.4 %	(11.8 - 15.6)	
	Platelet	271 x10(9)/L	(150 - 450)	
	Neutro Absolute	4.01 10(9)/L	(1.70 - 7.00)	
	Lymph Absolute	2.36 x10(9)/L	(0.90 - 2.90)	
	Mono Absolute	0.69 x10(9)/L	(0.30 - 0.90)	
	Eos Absolute	0.18 x10(9)/L	(0.05 - 0.50)	
	Baso Absolute	0.05 x10(9)/L	(0.00 - 0.30)	
	Differential?	Auto		
	Sodium Lvl	140 mmol/L	(135 - 145)	
	Potassium Lvl	^ 4.1 mmol/L	(3.5 - 5.1)	
	Chloride	^ 101 mmol/L	(98 - 107)	
	CO2	^ 24 mmol/L	(22 - 29)	
	AGAP	15 mmol/L	(10 - 20)	
	Alkaline Phosphatase	^ L 40 unit/L	(45 - 115)	
	Glucose Lvl	81 mg/dL	(70 - 139)	
	Creatinine	^ 1.07 mg/dL	(0.80 - 1.30)	
	EGFR (MDRD)	^ >60 mL/min/1.73m2	(>=60 -)	
	EGFR African American (MDRD)	^ >60 mL/min/1.73m2	(>=60 -)	
	BUN	^ 19 mg/dL	(8 - 24)	
	Calcium Lvl	^ 9.3 mg/dL	(8.6 - 10.3)	
	Protein Total	^ 7.3 gm/dL	(6.3 - 7.9)	
	Albumin Lvl	^ 4.5 g/dL	(3.5 - 5.0)	
	AST	17 unit/L	(8 - 48)	
	ALT	^ 11 U/L	(7 - 55)	
	Bili Total	^ 0.4 mg/dL	(- <=1.2)	
[REDACTED]	Hgb	14.8 g/dL	(13.5 - 17.5)	
	Hct	43.6 %	(38.8 - 50.0)	
	WBC	8.4 x10(9)/L	(3.5 - 10.5)	
	RBC	4.65 x10(12)/L	(4.32 - 5.72)	
	MCV	93.8 fL	(81.2 - 95.1)	
	RDW	13.3 %	(11.8 - 15.6)	
	Platelet	247 x10(9)/L	(150 - 450)	
	Neutro Absolute	5.38 10(9)/L	(1.70 - 7.00)	
	Lymph Absolute	2.20 x10(9)/L	(0.90 - 2.90)	
	Mono Absolute	0.65 x10(9)/L	(0.30 - 0.90)	
	Eos Absolute	0.10 x10(9)/L	(0.05 - 0.50)	
	Baso Absolute	0.05 x10(9)/L	(0.00 - 0.30)	
	Differential?	Auto		
	D-Dimer	^ <0.28 mcg/mL FEU	(- <=0.50)	
	Sodium Lvl	141 mmol/L	(135 - 145)	
	Potassium Lvl	^ 4.1 mmol/L	(3.5 - 5.1)	
	Chloride	^ 103 mmol/L	(98 - 107)	
	CO2	^ 26 mmol/L	(22 - 29)	
	AGAP	13 mmol/L	(10 - 20)	

Example of Labs: Your Institution's Report May Look Different

Flowsheet Print Request

Patient: [REDACTED]


Printed by: [REDACTED]

MRN: [REDACTED]

Event Date	Event	Result	Ref. Range	Status
	Glucose Lvl	85 mg/dL	(70 - 139)	
	Creatinine	^ 1.10 mg/dL	(0.80 - 1.30)	
	EGFR (MDRD)	^ >60 mL/min/1.73m2	(>=60 -)	
	EGFR African American (MDRD)	^ >60 mL/min/1.73m2	(>=60 -)	
	BUN	^ 17 mg/dL	(8 - 24)	
	Calcium Lvl	^ 8.9 mg/dL	(8.6 - 10.3)	
	Troponin-T	<0.01 ng/mL	(- <=0.01)	

Pathology Report

Example of Pathology Report: Your Institution's Report May Look Different



Age/Sex: [redacted]
DOB: [redacted]

Collection Date: [redacted]
Date Received: [redacted]
Report Date: [redacted]

S
U
R
G
I
C
A
L

P
A
T
H
O
L
O
G
Y

R
E
P
O
R
T

Tissue
bone, left foot

Clinical Diagnosis
non-pressure chronic ulcer of left foot

Final Diagnosis

Bone and soft tissue, left foot, excision:
Reactive and degenerative changes and chronic inflammation.

Gross

A. Part A is received in formalin labeled with the patient's name, medical record number, and "bone left foot", and consists of 4 2.5 x 1.5 x 1.5 cm fragments of bone and soft tissue consisting of phalangeal bones with overlying soft tissue. Representative sections are submitted as follows:

Cassette 1 soft tissue

Cassette 2 bone (after decalcification).

(CG/cg)



Intraop Anes/Circ RN Record

These are the documents used for
independent documentation of Surgeon of
Record

ANESTHESIA RECORD

PAGE OF 1 AGE 40 ASA 1 2 3 4 5 E

She [redacted]

Arterial Line	Radial	R L	Femoral	R L
CVP	U	R L	Subclavian	R L
Swan Ganz	U	R L	Subclavian	R L

IV Sedation for eye block note start/stop below

Anesthesia Stop [redacted] Anesthesia Stop [redacted]

Surgeon [redacted] Anesthesiologist [redacted] CRNA [redacted]

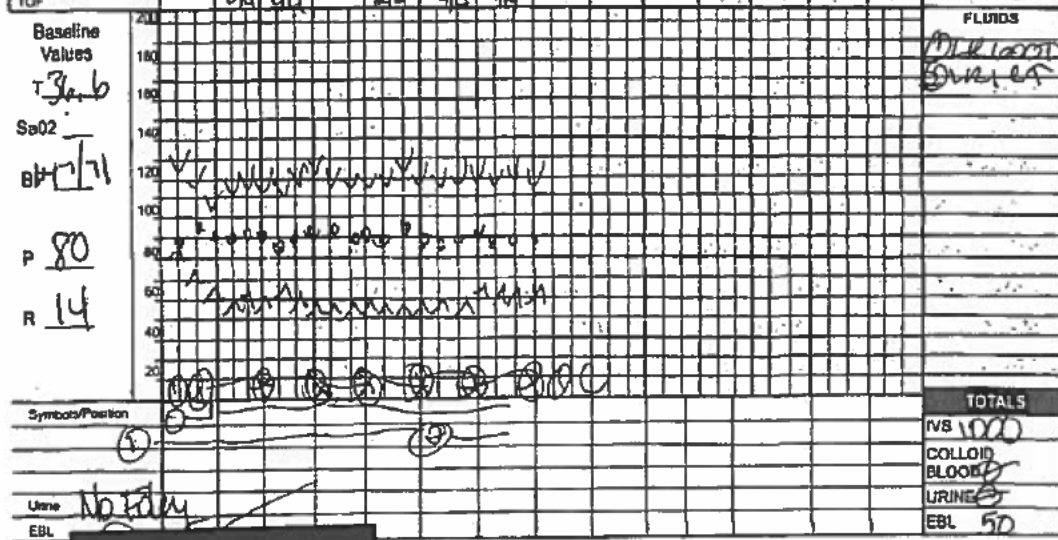
Diagnosis Open prostatectomy (1) 4th & 5th metastatic nodes

Procedure ORIF 4th & 5th metastatic nodes

Outpatient Inpatient GA SP Epi Block MAC present for induction

<input type="checkbox"/> Identified <input type="checkbox"/> Chart Reviewed <input type="checkbox"/> Permit Signed <input checked="" type="checkbox"/> Band checked <input type="checkbox"/> Surgical Site verification <input type="checkbox"/> Machine check prior to use # _____ Pre-anesthetic State: <input type="checkbox"/> Awake <input type="checkbox"/> Calm <input type="checkbox"/> Sleepy <input type="checkbox"/> Agitated <input type="checkbox"/> Uncomfortable <input type="checkbox"/> Sedative ordered <input type="checkbox"/> Uncooperative <input type="checkbox"/> Unresponsive <input type="checkbox"/> Safety Belt on <input type="checkbox"/> Armboard Restraints <input type="checkbox"/> Arms Tucked <input checked="" type="checkbox"/> Pressure points checked and padded <input type="checkbox"/> Positioning roll <input type="checkbox"/> Eye Care: <input type="checkbox"/> Ointment <input type="checkbox"/> Saline <input type="checkbox"/> Taped <input type="checkbox"/> Padded <input type="checkbox"/> Goggles	<input checked="" type="checkbox"/> Continuous EKG <input type="checkbox"/> Pulse Oximeter <input type="checkbox"/> Non-invasive B/P <input type="checkbox"/> Left <input type="checkbox"/> Right <input checked="" type="checkbox"/> Gas Analyzer <input type="checkbox"/> End Tidal CO2 <input type="checkbox"/> Airway Humidifier Sleigh <input type="checkbox"/> Precord. <input type="checkbox"/> Esoph <input type="checkbox"/> Nerve Stimulator <input type="checkbox"/> NG <input type="checkbox"/> OG <input type="checkbox"/> Fluid Warmer <input type="checkbox"/> Convection warmer <input type="checkbox"/> Foley <input type="checkbox"/> Upper body <input type="checkbox"/> Lower body <input type="checkbox"/> Hypotensive Technique <input type="checkbox"/> Hemodilution <input type="checkbox"/> Intraop Salvage <input type="checkbox"/> Endobronchial size _____ Fr	General: <input type="checkbox"/> Inhalation <input type="checkbox"/> Intravenous <input type="checkbox"/> LMA <input type="checkbox"/> Pre-Oxygenation <input type="checkbox"/> L.T.A. <input checked="" type="checkbox"/> Rapid Sequence <input type="checkbox"/> Cricoid Pressure Intubation: <input type="checkbox"/> ET size 7.0 <input type="checkbox"/> Agonist <input type="checkbox"/> Magill <input type="checkbox"/> R.A.E. <input type="checkbox"/> Laser <input type="checkbox"/> Cuffed <input type="checkbox"/> Uncuffed, leaks at _____ cm H2O <input type="checkbox"/> Magill <input type="checkbox"/> Direct <input type="checkbox"/> Fiber optic <input type="checkbox"/> Blind <input checked="" type="checkbox"/> Blade # 2 (Miller) mac <input checked="" type="checkbox"/> Secured @ 18 cm <input checked="" type="checkbox"/> ET CO2 present <input checked="" type="checkbox"/> SBSE <input type="checkbox"/> Atraumatic <input type="checkbox"/> Difficult <input checked="" type="checkbox"/> Attempts 0/1 <input type="checkbox"/> Position Unchanged Airway: <input type="checkbox"/> Oral <input type="checkbox"/> Nasal Oxygen: <input type="checkbox"/> Tracheotomy <input type="checkbox"/> Tpiece <input type="checkbox"/> Nasal Cannula <input type="checkbox"/> O2 mask <input type="checkbox"/> Arrived Intubated <input type="checkbox"/> NRB mask	<input type="checkbox"/> Time Out performed prior to block Regional: <input type="checkbox"/> Spinal <input type="checkbox"/> Epidural <input type="checkbox"/> Arise <input type="checkbox"/> Axillary <input type="checkbox"/> Paravertebral <input type="checkbox"/> Block <input type="checkbox"/> ITAP <input type="checkbox"/> Popliteal <input type="checkbox"/> Interspace Juc <input type="checkbox"/> Femoral <input type="checkbox"/> Other _____ <input type="checkbox"/> Right <input type="checkbox"/> Left _____ <input type="checkbox"/> US Guidance Image retained Local _____ Site _____ Needs _____ Level _____ Drug/Dose _____ Attempts X _____ Time _____ Signature _____
--	--	--	---

Monitoring Time Line	0	30	2:00	3:00	2:00	3:00	2:00	3:00	Totals
O ₂ Sat	100	100	100	100	100	100	100	100	100
FiO ₂ / PEEP	1.0 / 5	1.0 / 5	1.0 / 5	1.0 / 5	1.0 / 5	1.0 / 5	1.0 / 5	1.0 / 5	1.0 / 5
Spontaneous RR	12	12	12	12	12	12	12	12	12
SpO ₂	100	100	100	100	100	100	100	100	100
MAP	80	80	80	80	80	80	80	80	80
HR	80	80	80	80	80	80	80	80	80
Temp	37.5	37.5	37.5	37.5	37.5	37.5	37.5	37.5	37.5
ET CO ₂	35	35	35	35	35	35	35	35	35
ET Volume	500	500	500	500	500	500	500	500	500
RR	12	12	12	12	12	12	12	12	12
Peak Pressure	18	18	18	18	18	18	18	18	18
PEEP	5	5	5	5	5	5	5	5	5
TOF	0.4	0.4	0.4	0.4	0.4	0.4	0.4	0.4	0.4



Preop Antibiotics Drug/Dose

Mic 2gm @ 1604

Ofloxacin 400mg

Started at: _____

Incision at: 1924

Remarks:

FLUIDS

DLR 1000

500ml

Reversal Agents

Neostigmine 5 mg

Glycopyrronium 1 mg

SYMBOLS

X ANESTHESIA

○ OPERATION

∇ SUP CLIFF INCIDENT

↓ ARTERIAL LINE PRESSURE

S MEAN ARTERIAL PRESSURE

● PULSE

○ SPONT RESP

∇ ASSISTED RESP

⊕ CONTROLLED RESP

TOTALS

IVS 1000

COLLOID BLOOD

URINE

EBL 50

Example of Circulating Nurse Report: Your Institution's Report May Look Different



Nursing Intraop Record

Patient:



CC #:

MRN:

Acct #:



Sex:

DOB:



Patient Information

Admission Type:

OP

Visitors Waiting:

Spouse

Procedure Information

Procedure Date:



OR #:

OR 18

Sch Case Time:

Anesthesia Type

General

ASA:

IE

Case Type:

Emergency

Preop Diag:

Fracture; Foot, left

Postop Diag:

Fracture; Foot, left

Procedure:

ORIF 4 TH AND 5 TH METATARSAL LEFT FOOT WITH PRIMARY CLOSURE AND SPLINT

Procedure(s)

Surgeon

I&D, Extremity; LEFT FOOT



Primary

Open Reduction Internal Fixation Toe

Radiology Usage

C-Arm-Mini

Prep Location

Left ; Foot

Prep

Betadine paint

Position

Safety strap on ; Supine ; Arm(s) papooseed to side(s)

Consent Status

Anesthesia consent; Completed - copy on chart

Blood consent; Completed - copy on chart

Operative consent; Completed - copy on chart; Signed, Correct, Verbally confirmed.

Verification



Patient verification -- ID Band; Name; Age; Verbally Confirmed; Allergy Band, if applicable; Date of Birth